

Original Research Article

Functional outcome of patients undergoing open rotator cuff repair

Albin Savio, Nishara M. S.*

Department of Orthopaedics, Government Medical College, Kottayam, Kerala, India

Received: 01 June 2020

Revised: 17 July 2020

Accepted: 29 July 2020

***Correspondence:**

Dr. Nishara M. S.,

E-mail: nisharamohamed@gmail.com

Copyright: © the author(s), publisher and licensee Medip Academy. This is an open-access article distributed under the terms of the Creative Commons Attribution Non-Commercial License, which permits unrestricted non-commercial use, distribution, and reproduction in any medium, provided the original work is properly cited.

ABSTRACT

Background: Rotator cuff tears are a common source of shoulder pain. The incidence of rotator cuff damage increases with age and is most frequently due to degeneration of the tendon rather than injury from sports or trauma. Rotator cuff tear can be treated arthroscopically, arthroscopically assisted (mini-open) or by an open procedure. Because of the technical demands of arthroscopic repair many surgeons consider open repair for the treatment of rotator cuff tears. This study was done to evaluate the functional outcome of shoulder after open rotator cuff repair.

Methods: 26 patients with partial and complete rotator cuff tears underwent open rotator cuff repair and acromioplasty. Cases were followed up at 3 months and 6 months intervals and shoulder function was assessed using Constant-Murley scoring system and compared with the preoperative scores and analyzed using SPSS software.

Results: Mean preoperative constant score was 33.95 ± 7.545 while the mean constant score at 6 months post-surgery was 79.83 ± 8.51 which was highly significant according to paired t test. The difference between preoperative, 3 months and 6 months constant scores of complete and partial tear patients was found to be statistically significant.

Conclusions: There was highly significant increase in Constant-Murley score after 6 months in patients treated by open rotator cuff repair. Open repair still stands as an effective treatment for rotator cuff tears and doing acromioplasty during the procedure adds to better outcome after surgery.

Keywords: Open rotator cuff repair, Acromioplasty, Constant- Murley score

INTRODUCTION

Rotator cuff tears are a common source of shoulder pain. The incidence of rotator cuff damage increases with age and is most frequently due to degeneration of the tendon rather than injury from sports or trauma.¹ The etiology of rotator cuff tear is multifactorial and it has been mainly attributed to chronic attritional changes from impingement.² Rotator cuff tears can lead to a variety of clinical manifestations, including debilitating shoulder dysfunction and impairment. The goal of rotator cuff repair is to eliminate pain and improve function with increased shoulder strength and range of motion. Optimal repair of rotator cuff includes achievement of high fixation strength, minimal gap formation and maintenance of

mechanical stability under cyclical loading and proper healing of tendon to bone.³

The decision on how to treat rotator cuff injuries is based on the patient's severity of symptoms and functional requirements. For partial thickness rotator cuff tears, a non-operative program that includes activity modification, stretching and strengthening exercises, and anti-inflammatory medication is appropriate as initial treatment. Operative management is indicated if conservative management fails. Operative management of rotator cuff tear is usually required in patients with symptoms refractory to a conservative rehabilitation program. This is complicated by the fact that most of these patients are elderly and have many associated medical

problems. Since Codman and Ackerson's first rotator cuff pathology description, rotator cuff repair has been one of the most common surgical procedures performed in the shoulder.^{4,5}

A decision can be made to treat the tear arthroscopically, or arthroscopically assisted (mini-open) or by an open procedure. Addition of a rehabilitation plan to the above provide requisite nourishment and environment essential for the repaired and recovering tendons.⁶ Because of the technical demands of arthroscopic repair many surgeons consider open repair for the treatment of rotator cuff tears.

The objective of our study is to evaluate the functional outcome of shoulder after open rotator cuff repair for partial and complete rotator cuff tears.

MATERIALS AND METHODS

Study design

Prospective, observational study period of June 2017–November 2018.

Study population

All patients with partial and full thickness rotator cuff tear undergoing open rotator cuff repair in the department of orthopaedics, Government Medical College, Kottayam.

Sample size

According to a study by Vaidyar et al, the mean score for full thickness at final follow up after repair was 91.3 ± 1.3 .⁷ Using this data sample is calculated by the formula

$$N = [(Z\alpha + Z\beta)^2 \times S^2] / d^2$$

Standard deviation (s) = 1.3

Standard precision (d) = 0.5

$$\begin{aligned} \text{Sample size } n &= (1.96)^2 \times (1.3)^2 / (0.5)^2 \\ &= 6.492 / 0.25 \\ &= 25.96 \text{ i.e } 26 \end{aligned}$$

Inclusion criteria

Patients with partial and full rotator cuff tear undergoing open rotator cuff repair.

All patients of age 35 to 70 years.

Exclusion criteria

Patients having fractures around the shoulder joint.

Statistical analysis

Data was entered in Microsoft Excel software, and analysis done using SPSS version 20.0 software. The level of significance was p value <0.05 and high significance p value <0.01. The data is collected using the proforma. The

results were analysed at the end of the study and observations made.

Study procedure

After obtaining approval for the study from Institutional Review Board, written informed consent from patients having full or partial thickness rotator cuff tears undergoing open rotator cuff was taken. Age, sex, side, hypertension and diabetic status were noted in the proforma. Pre-operative constant score of the shoulder was calculated and recorded using Constant and Murley scoring system and then proceeded with surgery.

Patient was positioned supine on the operation table in beach chair position. Affected shoulder was scrubbed, painted and draped and surface markings were done. 4-6 cm incision was made from lateral to the anterior acromion toward the coracoid after infiltrating the skin with 10 ml of 1:500000 adrenaline to minimize bleeding. Care was taken to avoid injury to the axillary nerve. After mobilization of the subcutaneous tissue, the raphe between the anterior and middle deltoid was identified and split. A flap of deltoid with its periosteal attachment and the periosteal attachment of the trapezius was elevated approximately 2 cm onto the superior acromial surface.

After completing the anterior limb of the elevation, the coracoacromial ligament was resected using electrocautery. With the subacromial space exposed, the bursa along with all adhesions and soft tissue coverage from the acromial under surface was removed. Acromioplasty was then done by removing the portion of the acromion that projects anterior to the anterior border of clavicle using oscillating saw or an osteotome. Edges were then smoothed using a rasp.

After acromioplasty, rotator cuff tear was identified (Figure 1). Mobilization of the cuff was started posteriorly with the infraspinatus, using a blunt probe or a finger to release adhesions inside and outside the joint, and continued anteriorly to supraspinatus. If the supraspinatus and infraspinatus tendons were retracted so far that adequate length cannot be obtained with tendon mobilization, the capsule was incised at its insertion into the glenoid labrum. The end of the mobilized tendon was debrided to obtain a raw edge, taking care not to confuse the tendon with the overlying bursa.

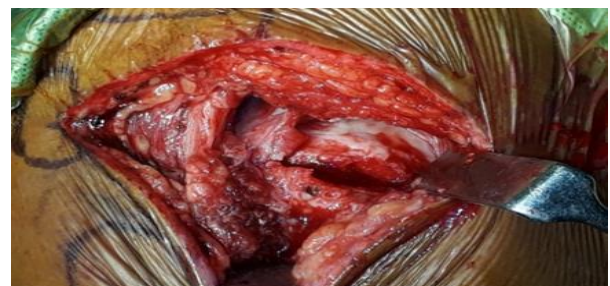

Figure 1: Rotator cuff tear.

The goals of mobilization were to obtain tissue of adequate strength, to position it anatomically for repair without damage to innervation and without compromise of deltoid function, and to decompress the subacromial space to prevent further mechanical impingement on repaired cuff tissue. A shallow trough was then created using a osteotome running the length of the exposed bone of the greater tuberosity to accommodate the thickness of the supraspinatus and infraspinatus tendons. The proximal edge was bevelled with a burr or rasp. Three no. 5 ethibond sutures were passed through the margins of tendons and fixed into the trough with tight approximation using drill holes (single row technique) (Figure 2). The area was copiously irrigate to remove all debris from the subacromial space.

The deltoid was then sutured with periosteum through drill holes into the acromion with nonabsorbable, ensuring that the reattachment is secure. The wound was then closed in the usual manner after attaining hemostasis.

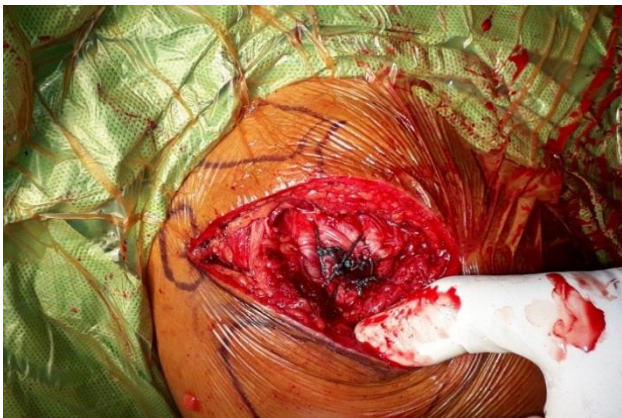

Figure 2: Rotator cuff tear post repair.

Following the procedure, the operated arm was immobilized in an abduction splint in 30° abduction (Figure 5). The splint was worn continuously for 6 weeks, except during bathing and exercises. The standard postoperative rehabilitation program is summarized below (Table 1).⁸

Table 1: Postoperative Rehabilitation protocol.

Time Period	Rehabilitation
0-6 weeks	Immobilization: splint
	Elbow/wrist: active ROM
	Shoulder: passive external rotation in adduction only
6-12 weeks	Shoulder: active ROM, avoid lateral abduction
	Stretching: forward flexion, internal rotation, external rotation
>12 weeks	Strengthening: deltoid, biceps, triceps, rotator cuff, scapular stabilizers
>6 months	Normal activities

Patient was followed up at 3 months and 6 months interval. Patient functional assessment was done based on pain relief, ability to carry on activities of daily living, strength and patient satisfaction post operatively. Results were finally evaluated using Constant and Murley shoulder scoring system and entered in a proforma.⁹

Constant score at 6 months was grouped as given in Table 6. All the data was then entered in excel sheet and analyzed using SPSS software.

RESULTS

Age and sex distribution

In our study majority of the patients were males and highest number of patients were in the age group of 51-60 years followed by age group 41-50 years.

Table 2: Distribution of study population according to age and sex.

Characteristics	Frequency	Percentage (%)
Age group (in years)		
31-40	1	3.8
41-50	10	38.5
51-60	11	42.3
61-70	4	15.4
Sex		
Male	14	53.8
Female	12	46.2

Side and degree of tear

In patients with right side (dominant) shoulder involvement, 11 (64.7%) had complete tear and 6 (35.3%) had partial tear. Out of 9 patients with left side (non-dominant) shoulder involvement, 5 (55.6%) had complete tear and 4 (44.4%) had partial tear.

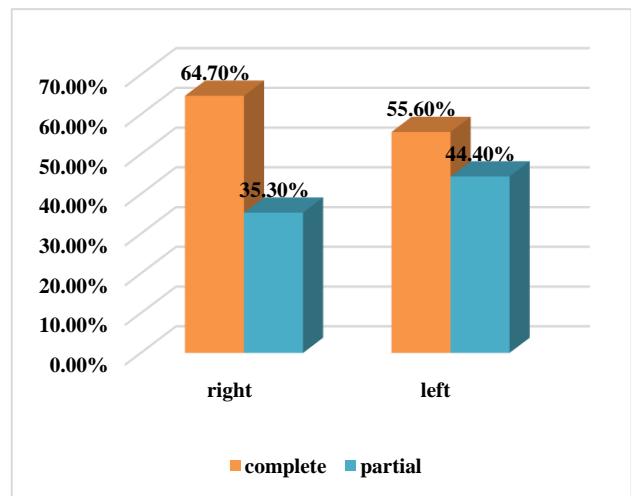


Figure 3: Distribution of study population according to side and degree of tear.

Pre-op and post-op constant scores

Mean pre-op constant score was 33.95 ± 7.545 with highest score of 48.0 and lowest score of 18.2. Mean constant score at 3 months followup was 69.72 ± 8.840 with range from 46.9 to 80.6. Mean constant score at 6 months post surgery was 79.83 ± 8.51 with least score of 56.4 and highest score of 92.6.

Table 3: Comparison of preoperative and 6 months postoperative constant score.

	Mean	N	Std. deviation	t	P value
Pre-op CS	33.95	26	7.545		
Post-op CS (after 6 months)	79.83	26	8.51	29.431	0.001

On evaluating difference in pre-op Constant-Murley score and post-op Constant Murley score after 6 months by paired sample t test, it was found to be highly significant with t value of 29.431 and p value of 0.001.

Preoperative photographs showing range of shoulder movements

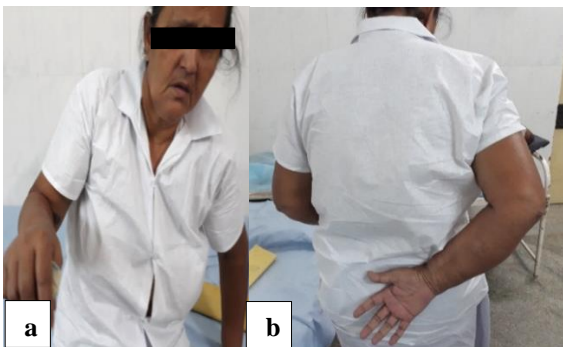

Figure 4: (a) Pre-op abduction and (b) pre-op internal rotation.

Post operative photographs after 6 months showing range of shoulder movements

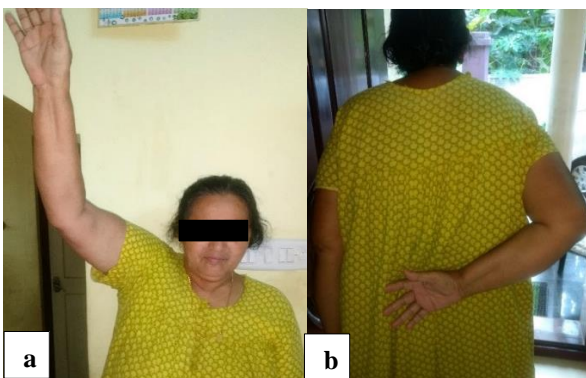

Figure 5: (a) Post-op abduction at 6 months and (b) post-op internal rotation at 6 months.

DISCUSSION

Rotator cuff tears can lead to a variety of clinical manifestations, including debilitating shoulder dysfunction and impairment. The goal of rotator cuff repair is to eliminate pain and improve function with increased shoulder strength and range of motion.

Epidemiological studies show that prevalence of rotator cuff tears increase with age. In our study only 1 (3.8%) patient was in the age group 31-40. 10 (38.5%) patients were between the age of 41-50, 11 (42.3%) were in the age group 51-60 and 4 (15.4%) were in the age of 61-70 with a mean age of $t 53.12 \pm 6.93$. Ultrasound studies by Tempelhof et al revealed that 13% of individuals in their fifth decade, 20% in their sixth decade and 31% in their seventh decade of life have RCTs. Studies by Kim et al and Yamaguchi et al show that older age is clearly associated with increase in the prevalence of rotator cuff tears.^{10,11} Sher et al reported that thirteen (28%) of forty-six patients who were more than sixty years old had a full-thickness tear.¹² Milgrom et al in a study conducted with ultrasonography, reported that fifteen (65%) of twenty three patients who were more than seventy years old had a rotator cuff tear.¹³

Our study showed a male predominance (54%) in both partial and full thickness tears. A study by Douglas Harryman et al in 1991 in 105 patients with rotator cuff tear showed 67% of the patients being men and 67% of the patients having their dominant side affected.¹⁴ This study shows that 65% *i.e.* 17 out of 26 patients had dominant side affected. Study by Yamaguchi et al in 2006 also had 65% patients having their dominant side affected.¹¹ Majority of the patients (61.5%) in this study had full thickness rotator cuff tears and no association was found between gender and side to the degree of tear using chi-square test.

Mean pre-operative constant score was 33.95 ± 7.545 and mean constant score at 6 months post-surgery was 79.826 ± 8.51 . This was highly significant according to paired t test with p value of 0.001. At 6 months follow up, 1 patient (3.8%) had poor outcome, 2 (7.7%) adequate, 8 (30.8%) had satisfactory, 14 (53.8%) had good and 1 (3.8%) had excellent Constant Murley scores. This was comparable to the study by Vaidyar et al in 2015 in which 30 patients with rotator cuff tears who underwent open repair were studied.⁷ Mean pre-op constant score in their study was 59.5 while the mean constant score at 2 years follow up was 91.5 which was highly significant. In a long term study of 9.9 years in 23 patients by Matthias et al open rotator cuff repair was found to be significantly effective in treating massive rotator cuff repairs with a relative post op constant score of 85.¹⁵ In a study conducted by Prasad et al from 2000 – 2003, 42 patients underwent open rotator cuff repair by a single surgeon and at 26 months follow-up there was significant increase in constant score with p value < 0.001 .¹⁶ This is also comparable to the results of the study by Harryman et al in 1991.¹⁴

In our study, mean pre-op constant score in patients with complete rotator cuff tear was 30.98 ± 7.053 and mean pre-op constant score for patients with partial rotator cuff tear was 38.68 ± 5.895 . At 3 months follow-up, mean constant score of partial complete tear patients was 66.74 ± 9.963 and that of partial tear patients was 74.48 ± 3.245 . At 6 months follow-up mean constant score of complete rotator cuff patients was 77.04 ± 9.495 and that of partial tear patients was 84.28 ± 3.891 . On evaluating using independent sample t test, difference between pre-op, 3 months and 6 months constant scores of complete and partial tear patients was found to be significant with p values of 0.007, 0.01 and 0.013 respectively. However this is in contrast with the study by Vaidyar et al in which no significant difference in functional outcome between patients with partial and full thickness rotator cuff tears at 2 years post repair.⁷

CONCLUSION

Majority of the patients with rotator cuff tears were males with their dominant side affected and were in the age group of 51-60. There was highly significant increase in Constant Murley score after 6 months in patients treated by open rotator cuff repair with a p value 0.001. Open rotator cuff repair still stands as an effective treatment for both partial and complete tendon tears and doing acromioplasty during the procedure adds to better outcome after surgery.

ACKNOWLEDGEMENTS

We express our thanks and gratitude to Professor Dr. M. A Thomas and Dr. Tomichan M C, Additional Professor, Orthopedics.

Funding: No funding sources

Conflict of interest: None declared

Ethical approval: The study was approved by the institutional ethics committee

REFERENCES

- Tempelhof S, Rupp S, Seil R. Age related prevalence of rotator cuff tears in asymptomatic shoulders. J Shoulder Elbow Surg. 1999;8:296-9.
- Neer CS 2nd. Anterior acromioplasty for the chronic impingement syndrome in the shoulder. J Bone Joint Surg. 1972;54(1):41-50.
- Bretzke CA, Crass JR, Craig EV, Feinberg SB. Ultrasonography of the rotator cuff: normal and pathologic anatomy. Invest Radiology. 1985;20(3):311-5.
- Codman EA, Ackerson IB. The pathology associated with rupture of the supraspinatus tendon. Ann Surg. 1931;93:348-59.
- Galatz LM, Griggs S, Cameron BD, Iannotti JP. Prospective longitudinal analysis of postoperative shoulder function: a ten-year follow-up study of full-thickness rotator cuff tears. J Bone Joint Surg (Am). 2001;83:1052-6.
- Sambandam SN, Khanna V, Gul A, Mounaswamy V. Rotator cuff tears: An evidence based approach. World J Orthop. 2015;6(11):902-18.
- Vaidyar JM, Kassim S, Shibli S, Safwan UH. Functional outcome of shoulder following mini open repair for rotator cuff injuries. Int J Cur Res Rev. 2015;7(7):40-4.
- Conti M, Garofalo R, Rose GD, Massazza G, Vinci E, Randelli M, Castagna A. Post-operative rehabilitation after surgical repair of the rotator cuff. Chir Organi Mov. 2009;93(1):55-63.
- Constant CR, Murley AHG. A clinical method of functional assessment of the shoulder. Clin Orthop Relat Res. 1987:160-4.
- Kim HM, Teefey SA, Zelig A, Galatz LM, Keener JD, Yamaguchi K. Shoulder strength in asymptomatic individuals with intact compared with torn rotator cuffs. J Bone Joint Surg Am. 2009;91:289-96.
- Yamaguchi K, Ditsios K, Middleton WD, Hildebolt CF, Galatz LM, Teefey SA. The demographic and morphological features of rotator cuff disease: A comparison of asymptomatic and symptomatic shoulders. J Bone Joint Surg Am. 2006;88:1699-704.
- Sher JS, Uribe JW, Posada A, Murphy BJ, Zlatkin MB. Abnormal findings on magnetic resonance images of asymptomatic shoulders. J Bone Joint Surg Am. 1995;77:10-5.
- Milgrom C, Schaffler M, Gilbert S, van Holsbeeck M. Rotator-cuff changes in asymptomatic adults: The effect of age, hand dominance and gender. J Bone Joint Surg Br. 1995;77:296-8.
- Harryman DT, Mack LA, Wang KY, Jackins SE, Richardson ML, Matsen FA. Repairs of the rotator cuff. Correlation of functional results with integrity of the cuff. J Bone Joint Surg Am. 1991;73(7):982-9.
- Zumstein MA, Jost B, Hempel J, Hodler J, Gerber C. The clinical and structural long term results of open repair of massive rotator cuff tears. J Bone Joint Surg Am. 2008;90:2423-31.
- Prasad N, Odumala A, Elias F, Jenkins T. Outcome of open rotator cuff repair: an analysis of risk factors. Acta Orthop Belg. 2005;71:662-6.

Cite this article as: Salvio A, Nishara MS. Functional outcome of patients undergoing open rotator cuff repair. Int J Res Orthop 2020;6(5):1082-6.