

Original Research Article

Cannulated cancellous screws versus dynamic hip screw in femoral neck fractures: a comparison in productive age group at tertiary care hospital of North India

Sakib Arfee¹, Akib Arfee^{2*}, Adnan Aadil Arfee³

¹Department of Orthopedics, ³Department of Surgery, Government Medical College, Jammu, Jammu and Kashmir, India

²Department of Radiodiagnosis and Imaging, Government Medical College, Srinagar, Jammu and Kashmir, India

Received: 15 November 2020

Revised: 25 November 2020

Accepted: 26 November 2020

*Correspondence:

Dr. Akib Arfee,

E-mail: arfeeakib@gmail.com

Copyright: © the author(s), publisher and licensee Medip Academy. This is an open-access article distributed under the terms of the Creative Commons Attribution Non-Commercial License, which permits unrestricted non-commercial use, distribution, and reproduction in any medium, provided the original work is properly cited.

ABSTRACT

Background: Since intracapsular fracture neck femur was recognized by Ambrose Pare almost 4 centuries back, the management of intracapsular neck femur fracture has undergone many changes. The multitude of various implants designed and techniques available for its treatment themselves indicate the inadequacy of the various methods of treatment. Objective was to compare cannulated cancellous screws (CCS) versus dynamic hip screw (DHS) in femoral neck fractures in productive age group.

Methods: This observational study with both prospective and retrospective data analysis of patients operated by different surgeons in same hospital setup has been conducted from March, 2018 to February, 2020 at the department of Orthopedics, Government Medical College (GMC), Jammu. 105 cases satisfying the inclusion criteria admitted in GMC Jammu were included clinically and radiologically. Total number of patients included in the study was 97 patients as 8 patients were lost to follow-up. Functional outcome was evaluated by using Harris hip scoring.

Results: In our study 8 CCS cases were lost to follow up. Total 97 of cases were followed up till one year both radiologically and clinically after a given time intervals and final assessment done on the basis of Harris hip score. Among 97 cases 71 were males most of them in age group of 41-45 years and 26 were females with 46-50 years age group predominance. 47.42% fractures were classified as type III in garden's staging.

Conclusions: DHS is a better implant than CCS in hands of doctors who lack of expertise and precision i.e. required for CCS in fracture neck femur in young adult patients.

Keywords: CCS vs. DHS, Fracture NOF, Tertiary care hospital, North India

INTRODUCTION

Since intracapsular fracture neck femur was recognized by Ambrose Pare almost 4 centuries back, the management of intracapsular neck femur fracture has undergone many changes. The multitude of various implants designed and techniques available for its treatment themselves indicate the inadequacy of the various methods of treatment. No single method of treatment has been able to achieve 100% result. In addition, even after the fracture gets united there

is a risk of avascular necrosis and late segmental collapse leading to poor functional result. This fracture hence has been called "unsolved fracture" by Dickson.¹

Fracture healing in femoral neck is different from long bone fractures because of elongated position of femoral neck within capsule, its precarious blood supply and absence of cambium layer of periosteum and the fracture neck of femur heals without external callus formation. Also being intracapsular it is bathed in synovial fluid

containing angiogenic inhibiting factors resulting in washing away of fracture hematoma. It is combination of all these factors which result in complications like non-union, segmental collapse and avascular necrosis of femoral head. There are other factors like severity of injury, amount of displacement, duration of injury and delay between injury and surgery, anatomical reduction, type of fixator, smoking etc which are important prognostic indicators.

Garden classification is the most commonly used classification system for femoral neck fractures where the fractures are divided into 4 groups according to the degree of displacement and fracture fragments and it can be used as guidance for treatment options and surgical implants.²

In type I fracture the impaction allows a significant amount of stability at the fracture site and the union following the fixation with multiple cannulated screws is nearly 100%.^{3,4}

The stability in garden type II fracture is minimal as there is no impaction and almost all subsequently displace if not internally fixed.⁴

Rates of nonunion and avascular necrosis for undisplaced fractures are low if these fractures are stabilized internally using multiple (two to four) cannulated screws.⁵ Swiontkowski determined that the best results were obtained with anatomical reduction and fixation with multiple screws.⁶

Objective of our study was only a small step to solve the big problem with means and methods easily available for the management of femoral neck fractures in young population of north India.

METHODS

This study was conducted at orthopedic department of Government Medical College, Jammu from March, 2018 to February, 2020. This is an observational study with both prospective and retrospective data analysis of patients operated by different surgeons in same hospital setup. 105 cases satisfying the inclusion criteria admitted in GMC Jammu were included clinically and radiologically. 8 patients from the cannulated cancellous screws (CCS) group were lost to the follow-up hence the total number of patients included in the study was 97 patients. 64 patients were operated with CCS and 33 with dynamic hip screw (DHS). No specific criterion was taken into consideration for selection of patients and their respective implants. The follow up period was for a year, Patients were followed up at 2 weeks, 6 weeks, 3 months and 3 monthly till 1 year. Functional outcome was evaluated by using Harris hip scoring.

After taking Ethical clearance from the institutional ethical committee all the patients selected for the study were examined according to protocol, associated injuries noted

and clinical and laboratory investigations carried out in order to get fitness for surgery. Associated co-morbidities, mechanism of injury, duration of injury, time delay between injury and surgery were noted. The collected data was evaluated using appropriate statistical methods and presented in various tabular and graphical formats accordingly. MS Excel was used as statistics software to perform all the statistical analysis in this study.

Exclusion criteria were pathological fracture patients, underage and overage (i.e.<18 and >60 years) patients were excluded from this study. All other patients after taking properly informed consent and in the age group of 18-60 years were included in this study.

RESULTS

In our study 8 CCS cases were lost to follow up. Total 64 of cases were followed up till one year both radiologically and clinically after a given time intervals and final assessment done on the basis of Harris hip score. Among 97 cases 71 were males most of them in age group of 41-45 years and 26 were females with 46-50 years age group predominance.

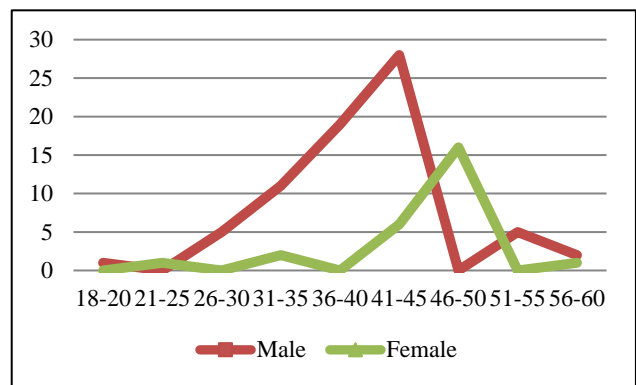


Figure 1: Age distribution.

Table 1: Garden staging.

Type	Number	Percentage
I	21	21.65
II	3	3.1
III	46	47.42
IV	27	27.83

Total 47.42% fractures were classified as type III in garden’s staging with road traffic accidents as the most common mode of injury overall. In our study there were no complications with DHS without derotation screw in comparison to CCS alone. In DHS group there were no infection and in CCS group 4 infection while different complications were noted among 33 out of 64 CCS cases. Total 12 cases of fracture collapse in CCS group were noted. 2 cases of non-union were noted among 64 CCS cases and non among the DHS group. Our study showed that delay in treatment increases the rate of complications

with incidence of avascular necrosis is 12.5 % in CCS group and 0% in DHS group.

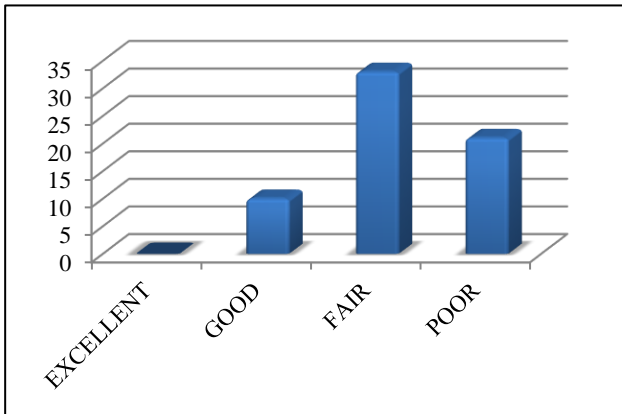


Figure 2: Results for CCS.

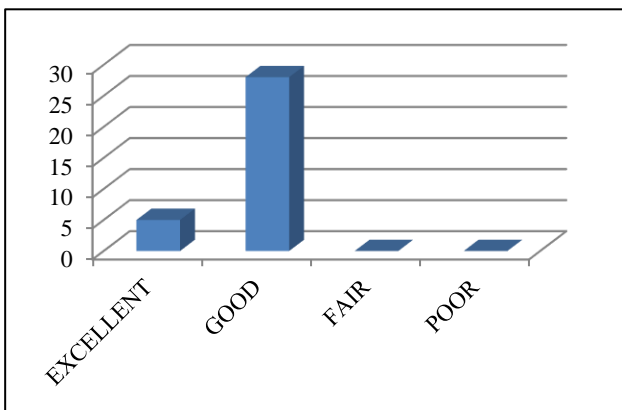


Figure 3: Results for DHS.

DISCUSSION

Internal fixation of these fractures is much better than arthroplasty because the patients native bone tissue is preserved. Various types of internal fixation devices are reported for stabilization of these fractures in young adults but there is inconsistent evidence in literature with regards to optimal fixation technique. Most authors agree that the best position is anatomical reduction or in slight valgus. It is important to prevent complications like nonunion and AVN. Hence is recommended to fix these fractures in anatomical position, in this study using CCS or DHS. Tronzo in 1974 identified more than 100 different available implants for ORIF of femoral neck fractures.⁷ However, if a surgeon chooses ORIF, he basically must decide between two consecrated techniques: CCS or a DHS. In our study DHS was found to give superior results than CCS fixation in femoral neck fractures. All of the fractures fixed using DHS showed good results while 33% showed fair and 21% patients showed poor results with CCS fixation. The present study is consistent with the study of Azhar Lakhani et al which showed excellent results in only 25.8% of CCS cases and 61.3% of SHS cases.⁸

As our study shows that DHS is better implant very good results in comparison to CCS for Fracture neck of femur. Our study is supported by study of Mandeep Singh et al which concluded that DHS is a better implant than CCS in management of fracture neck femur in young adults in Pauwels type II and III in terms of functional outcome but complication rate does not depend on the implant selection.⁹

In our study 8 CCS cases were lost to follow up. Total 64 of cases were followed up till one year both radiologically and clinically after a given time intervals and final assessment done on the basis of Harris hip score. Among 97 cases 71 were males most of them in age group of 41-45 years and 26 were females with 46-50 years age group predominance. 47.42% fractures were classified as Type III in garden's staging with road traffic accidents as the most common mode of Injury overall. There were similar findings by Sharma A et al in their study, the incidence of neck femur fractures was more in men as compared to women and mean age was 47.5 years with most common mode of injury being motor vehicle accidents.¹⁰

Our study was limited to a single tertiary hospital of north India and does not take into consideration the results and outcome of similar procedures done by other surgeons and procedures performed in different hospital setups hence the results of comparison are not 100% reliable.

CONCLUSION

CCS has a very steep learning curve when compared to the DHS as it needs anatomical reduction, appropriate screw placement, proper screw size etc. comparatively DHS is a very forgiving and sturdy implant. Hence DHS is a better implant than CCS in hands of doctors who lack of expertise and precision i.e. required for CCS in Fracture neck femur in young adult patients.

Funding: No funding sources

Conflict of interest: None declared

Ethical approval: The study was approved by the institutional ethics committee

REFERENCES

1. Dickson, James A. The unsolved fracture. J Bone Joint Surg. 1953;4:805-22.
2. Garden RS. Low-angle fixation in fractures of the femoral neck. J Bone Joint Surg. 1961;43B:647-63.
3. Luice RS, Fuller, Stephen, Burdick DC, Johnston RM. Early prediction of avascular necrosis of the femoral head following femoral neck fractures. Clinic Orthopaed. 1981;16:207-14.
4. Parker MJ, Banajee A. Surgical approaches and ancillary techniques for internal fixation of intracapsular proximal femoral fractures. Cochrane Database Syst Rev. 2005;18:2.
5. Asnis SE, Wanek-Sgaglione L. Intracapsular fractures of the femoral neck. Results of cannulated

- screw fixation. *J Bone Joint Surg Am*. 1994;76:1793-803.
6. Swiontkowski MF. Intracapsular fractures of the hip. *J Bone Joint Surg Am*. 1994;76:129-38.
 7. Tronzo RG. Symposium on fractures of the hip. Special considerations in management. *Orthop Clin North Am*. 1974;5:571-83.
 8. Lakhani AA, Mahajan N, Sonawane DV. A Comparative Study of the Management Of Fracture Neck Femur By Dynamic Hip Compression Screw With Derotation Screw Versus Three Cancellous Screws. *J Medic Thes*. 2014;2:5-8.
 9. Singh M, Sonkar D, Verma R, Shukla J, Gaur S. Comparison of the functional outcome of DHS versus CCS in Pauwels type II and III fracture neck femur in young adults. *Int J Orthoped Sci*. 2017;3:745-9.
 10. Sharma A, Sethi A, Sharma S. Treatment of stable intertrochanteric fractures of the femur with proximal femoral nail versus dynamic hip screw. *Revista Brasileira de Ortopedia*. 2017;53:1016.

Cite this article as: Arfee S, Arfee A, Arfee AA. Cannulated cancellous screws versus dynamic hip screw in femoral neck fractures: a comparison in productive age group at tertiary care hospital of North India. *Int J Res Orthop* 2021;7:44-7.