

## Original Research Article

# Outcome of locking compression plate fixation in the management of distal end femur fractures: one year hospital based study

Vishal Singh<sup>1\*</sup>, Avinash Gundavarapu<sup>2</sup>, Tejas Patel<sup>1</sup>, Alokeshwar Sharma<sup>1</sup>

<sup>1</sup>Department of Orthopaedics, Dhanwantri Hospital and RC, Jaipur, Rajasthan, India

<sup>2</sup>Department of Orthopaedics, Yashoda Superspeciality Hospital, Hyderabad, Telangana, India

**Received:** 22 February 2021

**Revised:** 22 March 2021

**Accepted:** 25 March 2021

### \*Correspondence:

Dr. Vishal Singh,

E-mail: [dr.vishalsingh1689@gmail.com](mailto:dr.vishalsingh1689@gmail.com)

**Copyright:** © the author(s), publisher and licensee Medip Academy. This is an open-access article distributed under the terms of the Creative Commons Attribution Non-Commercial License, which permits unrestricted non-commercial use, distribution, and reproduction in any medium, provided the original work is properly cited.

## ABSTRACT

**Background:** Distal femur fractures make up 6 to 7% of all femur fractures. Various plating options for distal femur fracture are conventional buttress plates, fixed-angle devices, and locking plates. This study was planned to evaluate and explore locking compression plate fixation in distal end femur fractures which is expected to provide a stable fixation with minimum exposure, early mobilization, less complications and a better quality of life.

**Methods:** The study was conducted as prospective clinical study in 20 skeletally mature patients with x-ray evidence of distal femur fracture fulfilling inclusion and exclusion criteria, operated with distal femur LCP plating. Patients were assessed radiologically and classified according to distal femur fracture classification and outcome graded as excellent, good, fair and poor based on Lysholm Knee Score.

**Results:** Out of 15 excellent outcome cases, 3 cases were type A1 fracture, 1 case had type A3, 2 cases had type B1 and B2 each, 5 cases had type C2 and 2 cases had type C3 fracture. 1 case with good outcome was type C3. 1 case with fair outcome was type B2. While 3 cases with poor outcome were type A1, A2 and C3.

**Conclusions:** The DF-LCP is an ideal implant to use for fractures of the distal femur. However, accurate positioning and fixation are required to produce satisfactory results. We recommend use of this implant in Type A and C, osteoporotic and periprosthetic fractures.

**Keywords:** Distal femur, DF-LCP, Lysholm score, Periprosthetic fracture

## INTRODUCTION

Distal femur fractures occur at approximately one-tenth the rate of proximal femur fractures and make up 6 to 7% of all femur fractures.<sup>1</sup> These fractures are unstable fractures, so they are difficult to treat. It also contributes to other complications i.e. infection, fixed flexion deformity, non-union. These complications make treatment of distal femoral fractures a difficult task for an orthopaedic surgeon.

Operative treatment is indicated for open fractures, displaced fractures, and fracture with arterial injury.

Multiple different plating options for distal femur fracture are conventional buttress plates, fixed-angle devices, and locking plates.<sup>2</sup>

However, there have been few outcome studies on distal femur fractures treated with locking compression plate, showing better results as compared to the conventional treatment like ante grade nailing or plate and screw fixation, but more data is required in India to evaluate its use.<sup>3</sup> Hence this study was planned to evaluate and explore locking compression plate fixation in distal end femur fractures which is expected to provide a stable fixation

with minimum exposure, early mobilization, less complications and a better quality of life.

## METHODS

The present study was prospective study conducted at Dhanwantri Hospital and Research Centre, Jaipur during the period of May 2014 to June 2015. The Institutional ethical committee approval was obtained prior to the study. A total of 20 cases with distal end femur fractures were studied. Sample size was calculated by considering the 80% of average number of patients presented with distal end femur fracture over the period of last three years treated with LCP plating.

### Inclusion criteria

Participant giving consent to enroll in the study. Age more than 18 years. Fracture extending into distal 15 cm of the femur including the distal femoral metaphysis and/or the articular surface of the distal femur.

### Exclusion criteria

Fracture with vascular injury. Surgical Participant not willing to enroll in the study. Age less than 18 years. Older than three weeks for closed fracture and 24 hours for open fractures. Pathological fractures. Compound fractures with extensive soft tissue damage. Old fractures with complications like infection, delayed union, nonunion and malunion.

### Operative procedure

After classifying the fracture according to AO classification and through pre-operative investigations, detailed informed consent was taken. Then the patient in Operation Theater was positioned supine on the radiolucent fracture table with a pad under buttock of affected limb. Skin preparation done with betascrub and the limb was properly draped. Swashbuckler's approach was used to open the fracture. Then midline lateral incision was taken. Quadriceps fascia sharply dissected from vastus lateralis muscle lateral to its merge with ilio-tibial band, which is separated laterally and dissection was continued till linea aspera. Lateral parapatellar arthrotomy done to expose the femoral condyle. Retractors placed below vastus lateralis and medialis and the distal femur exposed by displacing the patella medially along with ligating the perforating vessels. Fracture was reduced and checked by image intensifier. Desired hole LCDCP was applied on lateral aspect of femur and fixed with 6.5mm cancellous screws in femoral condyl and 4.5 mm cortical screws as per needed. Closed suction drain was applied and wound closed in layer and dressing was applied.

Post-operative management: Dressing and drain removed after 48hrs. Static quadriceps and knee bending exerciser were started on second post-operative day as tolerated by

patient. Sutures were removed between 10 to 14days according to healing.

### Assessment

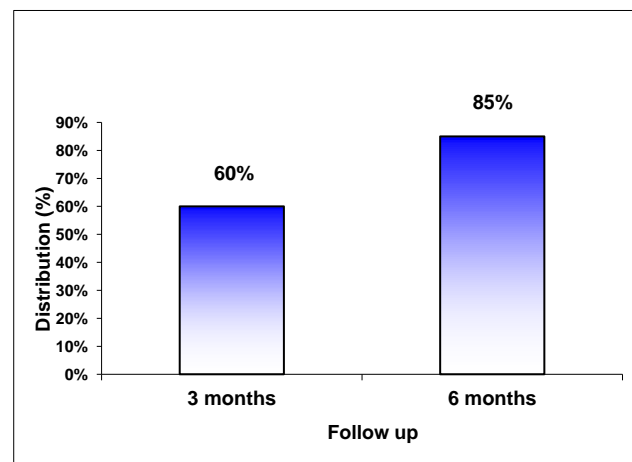
All the patients were followed up at the six weeks, three months and six months duration. The sixth week assessment included clinical assessment to exclude early complications related to the fracture or surgery, and a routine radiograph to evaluate the fracture position. The three months and six months appointment were scheduled for clinical assessment of fracture healing and a routine radiograph to assess union. Radiological union was assessed by the principal investigator at first, third and sixth month. Clinical data of union including fracture mobility, tenderness and pain was also obtained at each follow-up. The functional outcome was evaluated based on Knee society Score.

### Statistical analysis

The data collected was coded and entered on a spreadsheet prepared on Microsoft excel. Categorically the data was expressed as ratio, rate and percentage. The continuous data was expressed as mean  $\pm$  S.D. A 'p' value of less than or equal to 0.05 was considered as statistically significant. Type of study was cohort type prospective study.

## RESULTS

In the present study the 65% of patients were males and 35% were females. Majority of the patients (70%) were below the age of 45 years. The average age of patient was 40.9 years. The youngest patient was 20 years old and oldest patient was 80 years old. In the study right sided fracture was involved more than twice as compared to left sided fracture. The right to left ratio was 2.33:1. The RTA was the cause of injury in 60% of cases while 40% of patients reported fall.



**Figure 1: Percentage of patients showing radiological union at follow up.**

The commonest fracture according to AO classification was type C2 and C3 (45%) followed by extra-articular A1, A2 and A3 (30%) and partial articular B1 and B2 (25%). The most common post-operative complication was knee stiffness (25%) followed by delayed union (10%). One case (5%) each had malunion and infected- nonunion. 60% of patients had clinical union at three months and total 85% patient showed clinical union at six months. Similarly 60% of patient had radiological union at 3months and 85% at 6 months follow up.

In the study 75% patients were almost pain free at the final follow-up. 3 patients had severe pain, out of them 2 had delayed union and one had infected nonunion.

80% (16) of the patients had medio-lateral and antero-posterior mobility less than 5mm at 6 month follow up while other 15% (3) cases had abnormal mobility of more than 10 mm. 13 patients (65%) had knee flexion of more than 90 degree out of which 5 patients (25%) had knee flexion of more than 120 degree and 5 patients (25%) had less than 45degree. At final follow up mean flexion was 86.75 with standard deviation of 40.04. Quadriceps wasting of more than 5cm was present in 3 cases (15%) while 15 cases (75%) had wasting of muscle was minimal

(<2 cm). The extension lag was proportionate to quadriceps muscle wasting. Greater the quadriceps wasting, more extension lag was present.

In the present study 75% of patients had excellent functional outcome and 3 patients had poor results out of which 2 cases had delayed union and 1 had infected nonunion. It was observed that all patients with type A3, B1 and C2 had excellent outcome.

**Table 1: Follow-up pain.**

Pain	No. of cases	Percentage
None	12	60
On walking	1	5
Mild on occasion	2	10
Moderate	2	10
Severe	3	15

**Table 2: Shortening.**

Shortening	No. of cases	Percentage
< 1 cm	15	75
1-3 cm	2	10
>3 cm	3	15

**Table 3: Association between type of fractures and outcome.**

Type of fracture	Excellent		Good		Fair		Poor	
	No.	%	No.	%	No.	%	No.	%
A1	3	75	0	0	0	0	1	25
A2	0	0	0	0	0	0	1	100
A3	1	100	0	0	0	0	0	0
B1	2	100	0	0	0	0	0	0
B2	2	66.66	0	0	1	33.33	0	0
C1	0	0	0	0	0	0	0	0
C2	5	100	0	0	0	0	0	0
C3	2	50	1	25	0	0	1	25
<b>Total</b>	15	75	1	5	1	5	3	15

## DISCUSSION

Distal femoral fractures are associated with high-energy trauma (in the youngsters) and osteoporotic bones (in the elderly). Metaphyseal comminution is a challenge to conventional plate fixation. The locking compression plate (LCP) forms a fixed angle construct and enables placement of the plate without any contact to the bone.<sup>4</sup>

It can therefore be used in metaphyseal comminution. The pull-out strength of locking screws is substantially higher than that of conventional screws, and it is difficult for one screw to pull out or fail unless all adjacent screws do so. This enables a better hold in osteoporotic bones. The LCP

acts as an internal fixator and can be used for minimally invasive plate osteosynthesis (MIPO).<sup>5</sup>

Various treatment methods have been used for distal femoral fractures. They include direct-indirect reduction, open-minimal invasive approaches, and open-slipped techniques, and involve condylar plates, dynamic condylar screws, condylar buttress plates, anterograde nails, retrograde nails, internal fixators, and external fixators.<sup>6</sup> Good fixation outcomes depend on bone quality, fracture complexity, and surgical techniques. In our series, the patients were relatively young, and the fractures were mainly extra-articular, which is not difficult to treat even with other fixation devices.

This study was planned to evaluate and explore locking compression plate fixation in distal end femur fractures which is expected to provide a stable fixation with minimum exposure, early mobilization, less complications and a better quality of life.

In present study commonest type of fracture was intra-articular C2 and C3 (45%) followed by extra-articular A1, A2 and A3 (30%) and partial articular B1 and B2 (25%). In study of Yeap EJ7 out of 11 patients patients had type A (extra-articular) and 4 had type C (intra-articular).<sup>7</sup>

In this study 18 cases (90%) of patients required operative time of < 90 minutes while 2 cases (10%) there was intra-operative difficulties in fracture reduction required longer operative time more than 90 minutes. In study of Yeap 7 operative time ranged from 80-180 minutes, with an average of 119.2 minutes. While in study of Srinath.S.R 8 operative time ranges from 80 to 130 minute with an average of 101 minute.

Commonest late complication was knee stiffness. The knee flexion <45 degree was present in 5 cases (25%) out of which 1 had infected non-union, 1 had mal-union and 1 case had delayed union. In a study of Yeap, he reported the complication of implant fracture in one patient, leading to revision surgery with another LC-DCP, one mal-alignment and one plate cut through due to poor bone quality and fixation.<sup>7</sup> There were no non-unions, deep infection or removal of implants due to ilio-tibial tract pain. Bohra et al reported in his study that out of 40 patients 1 patient went for non-union, 1 presented with delayed union and 2 had superficial infection.<sup>8</sup> While in study of Srinath 8 out of 20 patients had shortening, 1 had varus mal-alignment.<sup>9</sup> Borthakur 10 in their series of 32 patients, 4 had implant failure and 2 had wound infection.

In this study the clinical and radiological union was noted in 12 cases (60%) of patients at three months and 85% cases (17 out of 20) had union at final follow up. Srinath reported 70% patients had clinical and radiological union at 4.5 month and 100% union at 7 month.<sup>8</sup>

In this study at final follow up 13 patients (65%) patients had knee flexion of more than 90 degree out of which 5 patients (25%) had more than 120 degree knee flexion.<sup>5</sup> patients (25%) had knee flexion less than 45degree. Mean flexion was 86.76 degrees with standard deviation of 40.04. In study of Srinath 60% of patients had knee flexion of 110 degree with mean flexion 104 degree.<sup>8</sup> While Bohra reported 50% of patients had knee flexion of 120 degree with mean flexion was 111 degree.<sup>9</sup>

Based on Knee score, 75% of patients had excellent functional outcome and 5% had good, 5% had fair while poor outcome was noted in 15% of patients. The outcome was comparable in both the sexes. In study of Borthakur 32 patients were evaluated based on knee society score excellent outcome noted in 13 patients (40.63%), 17 (53.12%) had good outcome while 2 (6.25%) cases had

poor outcome.<sup>10</sup> In study of Srinath 20 patients were evaluated based on neer's score 65% had excellent, 15% had good, 20% had fair and none had poor outcome.<sup>8</sup> In study of Yeap using schatzker scoring system results showed that 4 patients had excellent results, 4 good, 2 fair, 1 failure.<sup>7</sup>

In this study of the 15 patients with excellent outcome, all the patients (100%) aged 46 to 60 years and more than 60 years had excellent outcome while 70.00% of patients aged less than 30 years and 50% of patient age 31 to 45 years had excellent outcome and this difference was statistically not significant (p=0.2209). In our study it was observed that, all patients with type A3, B1 and C2 had excellent outcome. A retrospective study was done by Yeap in Malaysia in 2004 out of 4 patients 3 were below 30 years and 1 was above 60 years while 2 had type A1 and 1 had type A3 and C3 each.<sup>7</sup> Bipul reported 13 excellent patients with 4 were <30 years, 8 were 30-60 years and 1 was >60 years while 7 patients had type A, 5 had type B and 1 had type C fracture.<sup>10</sup>

## CONCLUSION

The DF-LCP is an ideal implant to use for fractures of the distal femur. However, accurate positioning and fixation are required to produce satisfactory results. We recommend use of this implant in type A and C, osteoporotic and periprosthetic fractures.

*Funding: No funding sources*

*Conflict of interest: None declared*

*Ethical approval: The study was approved by the institutional ethics committee*

## REFERENCES

1. Rockwood and Green's. Fractures in adults. Bucholz R, Heckman J, editors. Lippincott Williams and Wilkins. 6th edition. 2006;1916-65.
2. Schatzker J, Lambert DC. Supracondylar Fractures of the Femur. *Clin Orthop.* 1979;138:77-83.
3. Schutz M, Muller M, Regazzoni P. Use of the Less Invasive Stabilization System (LISS) in patients with distal femoral (AO33) fractures: a prospective multicenter study. *Arch Orthop Trauma Surg.* 2005;125(2):102-8.
4. Wagner M. General principles for the clinical use of the LCP. *Injury* 2003; 34 (Suppl 2): B31-42.
5. Frigg R. Locking Compression Plate (LCP). An osteosynthesis plate based on the Dynamic Compression Plate and the Point Contact Fixator (PC-Fix). *Injury.* 2001;32 (Suppl 2):63-6.
6. Hontzsch D. Distal femoral fracture—technical possibilities [in German]. *Kongressbd Dtsch Ges Chir Kongr.* 2001;118:371-4.
7. Yeap EJ, Deepak AS. Distal Femoral Locking Compression Plate Fixation in Distal Femoral Fractures: Early Results. *Malaysian Orthopaedic Journal.* 1(1):12-17.

8. Srinath SR, Kiran GU. Clinical study of locking compression plate fixation in supracondylar fractures of femur in adults. *J International Academic Res Multidisciplinary*. 2015;3(6):372-80.
9. Arvindkumar B, Sharma D, Shrivastav C. Distal Femoral Fractures Fixation by Locking Compression Plate: Efficacy & Complications. *Indian J Applied Res*. 2015;5(10):691-4.
10. Borthakur B, Hence B, Haque R, Jindal S. Results of locking compression plate in distal femur fracture. *J Med Thesis*. 2016;4(1).

**Cite this article as:** Singh V, Gundavarapu A, Patel T, Sharma A. Outcome of locking compression plate fixation in the management of distal end femur fractures: one year hospital based study. *Int J Res Orthop* 2021;7:597-601.