

Original Research Article

A comparative study of 70 cases of inter-trochanteric fracture femur treated with dynamic hip screw and proximal femoral nailing

Gaurav Singla*

Department of Orthopaedics, Adesh Hospital, Ambala Cantt, Haryana, India

Received: 20 December 2016

Revised: 18 January 2017

Accepted: 31 January 2017

***Correspondence:**

Dr. Gaurav Singla,

E-mail: gaurav.singla@yahoo.co.in

Copyright: © the author(s), publisher and licensee Medip Academy. This is an open-access article distributed under the terms of the Creative Commons Attribution Non-Commercial License, which permits unrestricted non-commercial use, distribution, and reproduction in any medium, provided the original work is properly cited.

ABSTRACT

Background: Inter-trochanteric fracture femur is a common and grievous injury, mostly suffered in elderly people. It accounts for approximately half of hip fractures in elderly and out of this, more than 50% of fractures are unstable. In old age, it occurs mostly due to trivial trauma. Various procedures of internal fixation had been proposed as a treatment. DHS considered to be the standard procedure for comparison of outcomes. The advantage of proximal femur nailing fixation is that it provides a more biomechanically stable construct by reducing the distance between hip joint and implant. The goal of this study is to compare the clinical and radio-graphical results of the DHS and PFN for the treatment of Intertrochanteric hip fractures (load bearing vs. load sharing).

Methods: Seventy patients (more than 55 years old) presented to Adesh Hospital from March 2015 to November 2015 with trochanteric fracture femur. Patients were treated with osteosynthesis with dynamic hip screw (DHS) and proximal femoral nailing (PFN). The clinical results were compared between the dynamic hip screw and proximal femoral nailing groups of 35 patients each. All surgeries done on traction table and were followed up at regular intervals of 4 weeks, 6 weeks, 8 weeks, 10 weeks, 12 weeks, 6 months and at 1 year.

Results: We observed no statistically significant difference between two groups in view of late & early complications and time to union. We observed significantly better outcomes in PFN group for unstable inter-trochanteric fractures and in unstable fractures reduction loss is significantly lower in PFN group.

Conclusions: We concluded that PFN may be the better fixation device for most unstable inter-trochanteric fractures.

Keywords: Inter-trochanteric fracture femur, Dynamic hip screw, Proximal femoral nailing

INTRODUCTION

Extracapsular fractures (intertrochanteric and sub-trochanteric fractures) primarily involve cortical and compact cancellous bone. Because of the complex stress configuration in this region and its nonhomogeneous osseous structure and geometry, fractures occur along the path of least resistance through the proximal femur.¹ Inter-trochanteric fractures account for approximately half of the hip fractures in elderly; out of this, more than 50% fractures are unstable.^{2,3} The goal of treatment of any intertrochanteric fracture is to restore mobility safely and efficiently while minimizing the risk of medical

complications and restore the patient to pre-operative status. The dynamic hip screw (DHS) has gained widespread acceptance in the last two decade and is currently considered as the standard device for comparison of outcomes. DHS gives good results but sometimes not suitable particularly in unstable inter-trochanteric fractures. The advantage of proximal femur nailing fixation is that it provides a more biomechanically stable construct by reducing the distance between hip joint and implant.⁴ These are load sharing devices; so early weight bearing can be allowed. The biomechanical advantage of intramedullary devices is important particularly in unstable trochanteric and sub-trochanteric

fractures.^{5,6} The goal of this study is to compare the clinical and radio-graphical results of the DHS and PFN for the treatment of Inter-trochanteric hip fractures (load bearing vs. load sharing).

METHODS

A prospective randomized and comparative study was conducted on the patients admitted in the Department of Orthopedics in Adesh Hospital from March 2015 and November 2015. In this study, 70 cases of inter-trochanteric fractures femur above the age of 55 years were included. Patients were divided into two groups of 35 patients each. The first group was managed with proximal femoral nail (PFN) while second group was treated with dynamic hip screw (DHS). Eligibility criteria for the patients included in the study were patients who were in the age group of more than 50 years of either sex, intertrochanteric fracture type (OTA classification) without any systemic or psychiatric illness, patients fit for anaesthesia.

The exclusion criteria were patients unfit for the surgery, with compound or pathological fractures, admitted for re-operation, those who have not given written consent for surgery, fractures associated with poly-trauma, pre-existing femoral deformity, preventing hip screw osteosynthesis or intra-medullary nailing and sub-trochanteric fractures, or fractures extending 5 cm distal to the inferior border of the lesser trochanter were excluded from study group.^{2,3,9,10}

Patients were managed with analgesics, then all preoperative investigations done required for intervention. If any wound or open injury found, antibiotics given. Radiographic examination was done to assess the type, pattern, extent and displacement of fracture.

For each of the 70 inter-trochanteric hip fractures the following parameters were recorded.

- Sex,
- Age at the time of fracture,
- Fracture type (AO/OTA classification),
- Total operative time (the time that closed reduction was started to the time that the wound sutured),
- Time to union (radio-graphical confirmation), and
- Complications (early and late).

Patients were evaluated before surgery and time from injury to surgery was (1-3 days). All surgeries were done on traction table and implant used for surgery according to surgeon's choice.

The present study was undertaken in patients more than 55 years of age with the objectives to compare the

dynamic hip screw and the proximal femoral nail method of fixation in intertrochanteric fracture of femur in the adults with respect to intra operative parameters (total duration of surgery, intraoperative blood loss and intraoperative complication), to compare the functional outcome with respect to union of the fracture, functional return, and complications in the two groups, to determine which implant would be ideal for which fracture type so as to provide the best results with the least complications and to study the long-term follow up of the two groups with respect to any residual impairment of function, chronic infection and overall tolerability of implant.

Surgical techniques

For DHS, through lateral approach, 7 cm to 8 cm long incision was made along the outer side of the femur bone Under the C-arm, the procedure was performed. A guide wire was inserted into the head of femur inferiorly on AP view and central or posteriorly on lateral view. Then reaming done with triple reamer. A suitably sized Richard's screw was inserted and position was verified with image intensification. Then DHS plate put inside with cortical screws. For PFN, Reduction was carried out under C-Arm. Then entry taken from tip of greater trochanter. Reaming done with gradually increasing size of reamers. Then fixation of fracture done with short proximal femoral nail (25 cm length) an intramedullary nail, two proximal femur neck screws and distally locking screw.

The duration of surgery as calculated from the time of surgery incision to skin closure was counted. The clinical outcome for each group was analyzed, and intraoperative, early (within first month after hip fracture repair), and late complications (after first month) were recorded.

Patients followed up at regular intervals of 4 weeks, 6 weeks, 8 weeks, 12 weeks, 14 weeks, 6 months and at 1 year. Their functional outcome was assessed with Harris hip scores.

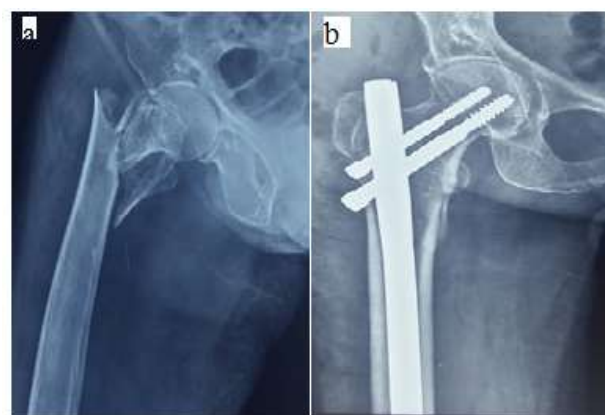


Figure 1: a) Preoperative X-ray showing unstable intertrochanteric fractures in PFN group; b) Postoperative X-ray in PFN group.

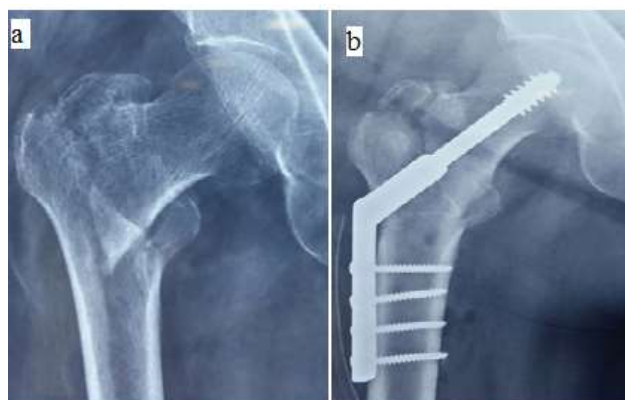


Figure 2: a) Preoperative X-ray showing unstable intertrochanteric fractures in DHS group; b) Postoperative X-ray in DHS group.

RESULTS

The study included 70 cases of inter-trochanter fractures. Out of these, 35 were treated by proximal femoral nailing and 35 were treated by dynamic hip screw. In our study, maximum age was 79 years and minimum age was 55 years. The average age was 67 years. In both groups, 15 patients were male and 20 were female patients as shown in Table 1.

Table 1: Characteristics of the patients among the study groups.

Characteristics	DHS	PFN
Sex		
Male	15	15
Female	20	20
Age group (55-79)	35	35
Fracture pattern		
A1	21	13
A2	11	15
A3	03	07

According to AO/OTA classification.² A1 fractures are simple, two-part fractures; A2 fractures have multiple fragments; A3 fractures includes reverse oblique and transverse fracture patterns.

Table 2 shows the average duration of surgery for the PFN was around 65 min while for DHS time was around 61 min. So, in case of duration of surgery, there is no significant difference between the two groups.

Table 2: Duration of surgery.

Time	DHS	PFN
	61 minutes	65 minutes

Table 3 shows the average blood loss in the PFN group was 152 ml and in the DHS group was 275 ml. The blood loss is less in PFN than DHS.

Table 3: Average blood loss.

Blood Loss	DHS	PFN
	275 ml	152 ml

Partial weight bearing started at 04 weeks in stable IT fracture cases whether treated with PFN and DHS and in such cases full weight bearing started at 10 weeks. In stable IT fractures, radiological signs of union seen at 10 weeks.

Table 4 shows the average time for partial weight bearing in unstable IT fractures was at 06 weeks (42 days) in PFN group while 08 weeks (56 days) in DHS group and the average duration for full weight bearing was at 12 weeks (84 days) in PFN group while 14 weeks in DHS group.

Table 4: Average time for weight bearing.

	DHS	PFN
Partial weight bearing	8 weeks	6 weeks
Full weight bearing	14 weeks	12 weeks

Table 5 illustrates that the average radiological union time was 12 weeks for PFN group while 14 weeks for DHS group.

Table 5: Average time for union.

	DHS	PFN
Radiological union	14 weeks	12 weeks

Non-union is not reported in our series. Malunion is reported in 01 case treated with PFN and in 02 cases treated with DHS in unstable IT fractures. At 1 year, all patients walked without any support.

Table 6 shows that out of 35 cases treated with PFN, iatrogenic fracture of lateral cortex occurred in one case for which procedure had to be abandoned and later on revised with long stem total hip replacement. In one case treated with PFN, intraoperatively fracture displacement occurred but fracture united.

Table 6: Complications.

Intraoperative complications	PFN group- no. of patients (%)	DHS group- no. of patients (%)
Failure to achieve close reduction	None	None
Iatrogenic fracture of lateral cortex	1 (2.86%)	None
Fracture displacement by nail insertion	1 (2.86%)	None

No complications occurred in patients with stable I/T fractures. All complications occurred in unstable I/T fractures. In this study, patients with excellent results are 24 (68.57%) in group 1 and 22 (62.86%) in group 2.

Table 7 shows the early and late complications occurring in both the groups. No infection and Implant failure reported in our series.

Table 7: Early and late complications.

Early complications	PFN group- no. of patients (%)	DHS group- no. of patients (%)
Superficial infection	0	0
Hematoma	0	0
Deep vein thrombosis	0	0
Late complications		
Malunion	1 (2.86%)	2 (5.71%)
Deep infection	0	0
Implant failure	0	0
Shortening (\geq 1cm)	1 (2.86%)	2 (5.71%)
Screw cut out	0	0

Table 8 shows the patients with good results are 7 (20%) in group 1 and 8 (22.86%) in group 2. Patients with fair results are 2(5.714%) in group 1 and 3(8.57%) in group 2. Patients with poor results are 2 (5.714%) in group 1 and 2 (5.71%) in group 2. In PFN group, one patient with poor result is added because of splintering of lateral cortex and due to which procedure is abandoned.

Table 8: Comparison of results according to Harris hip score among the study groups.

Results	PFN group- no. of patients (%)	DHS group- no. of patients (%)
Excellent	24 (68.57)	22(62.86)
Good	7(20.00)	8(22.86)
Fair	2(5.714)	3(8.57)
Poor	2(5.714)	2(5.71)

Harris hip score grading: less than 70 points-poor; 70-79 points -fair; 80-89 points- good; 90-100 points-excellent.

At the end of 1 year follow up, although Harris hip score is better in PFN treated group than DHS group, but it is not much significant.

DISCUSSION

The need for internal fixation and early mobilisation of patients with inter-trochanteric fractures is well accepted. It reduces the mortality and morbidity and also improves the functional outcomes with early mobility and preventing mal-union or non-union. The controversy still

exists regarding the best treatment and intramedullary vs. extramedullary implants. Various studies are being published but still controversy exists.

Majority of patients with these fractures are elderly with osteoporotic bones and have history of low energy trauma like simple fall at home. Cummings et al reported that inter-trochanteric fractures are the commonest fractures of hip.¹² Duration of surgery for PFN and DHS was almost similar but amount of blood loss was higher in DHS group. Khan et al compared the outcomes of fixation with PFN and DHS in unstable proximal femoral fractures in 70 patients.¹³ Operation duration was similar in both groups although blood loss was significantly low in PFN group (PFN-200 mls, DHS-375 mls).

In unstable trochanteric fractures, partial weight and full weight bearing was started early in PFN group than DHS group and Full weight bearing was started only after radiological union and it occurred earlier in PFN group. Issa et al showed similar results in his study.¹⁴

Average fracture union time was 12 weeks in PFN group and 14 weeks in DHS group in unstable trochanteric fractures. Mal-union occurred in 2 (5.71%) patients in DHS group while in 1 (2.86%) patient in PFN group. Femur shortening more than 1 cm. occurred in 2 (5.71%) patients in DHS group and in 1 (2.86%) patient in PFN group. No non-union reported in our series. No implant failure reported in both groups of this series while according to Lunsjo et al average fracture fixation failure rate is about 10% in unstable inter-trochanteric fractures.¹⁵

Complications such as malunion, femur shortening was slightly higher in DHS group. Although PFN seems to be a better implant in patients with unstable inter-trochanteric fractures but it is technically demanding as we encountered intraoperative complications as iatrogenic fracture of lateral cortex in one patient and fracture displacement by nail insertion in another patient. Functional outcome was assessed with Harris hip score and it was better in cases of unstable inter-trochanteric fractures treated with PFN and it was same in stable inter-trochanteric fractures in both groups.

CONCLUSION

We conclude that unstable intertrochanteric fracture can be better treated with proximal femoral nail inspite of technical difficulties. Patients with unstable inter-trochanteric fractures treated with PFN had less complications, better functional outcomes, earlier radiological union and earlier weight bearing.

Funding: No funding sources

Conflict of interest: None declared

Ethical approval: The study was approved by the institutional ethics committee

REFERENCES

1. Carter D, Hayes W. The Compressive Behavior of Bone as a Two-Phase Porous Structure. *J Bone & Joint Surg.* 1977;59(7):954-62.
2. Rockwood Charles A, Green David P, Bucholz, Robert W. In: Robert BW, James Heckman D, Charles Court Brown M, editors. *Rockwood and Green's Fractures in Adults.* Volume 2. 6th ed. Philadelphia : Lippincott Williams & Wilkins; 2006: 1827-1844.
3. David Lavelle G. Fractures and dislocations of the hip. In: Canale ST, editor. *Campbell's Operative Orthopaedics.* Chapter 52. Volume 3. 11th edition. 2008: 3237-3308.
4. Kish B, Sapir O, Carmel A, Regev A, Masrawa S. Full weight bearing after unstable per and subtrochanteric fracture using proximal femur nail. *J Bone and Joint Surg (Br).* 2001;83:289.
5. Sermon A, Broos PLO. The use of PFNA in treatment of intertrochanteric fractures. *Folia Traumatologica.* 2007:48-52.
6. Babhulkar SS. Management of trochanteric fracture. *Indian J Orthop.* 2006;40:210-8.
7. Christian B. The proximal femoral nail - a minimal invasive treatment of unstable proximal femoral fractures. *Acta Orthop Scand.* 2003;74(1):53-8.
8. Ely Steinberg L, Blumberg N, Deke S. The fixation proximal femur nailing system: biomechanical properties of the nail and a cadaveric study. *J Biomechanics.* 2005;38:63-8.
9. Pajarinen J. Pertrochanteric femoral fractures treated with a dynamic hip screw or a proximal femoral nail. A randomized study comparing postoperative rehabilitation. *JBJS (Br).* 2005;87(1):76-81.
10. Nuber S, Schoweiss T, Ruter A. Stabilization of unstable trochanteric femoral fractures: dynamic hip screw with trochanteric stabilization plate vs Proximal femoral nail. *J Orthopaedic Trauma.* 2003;17(4):316-7.
11. Ramakrishnan M, Prasad SS, Parkinson RW, Kaye JC. Management of subtrochanteric femoral fractures and metastases using long proximal femoral nail. *Injury.* 2004;35:184-90.
12. Cummings SR, Rubin SM, Black D. The future of hip fractures in united States: Number, costs and potential effects of postmenopausal estrogen. *Clin Orthop.* 1990;252:163-6.
13. Ishrat AK. O1013 To nail or to screw? *J Bone Joint Surg.* 2004;86:225-6.
14. Khaled I, Khalil A, Mossa W. Trochanteric Fractures. The best method of treatment. *Tanta Med Sc J.* 2008;3(2):204-14.
15. Lunsjo K. Extramedullary fixation of 569 unstable intertrochanteric fractures. A randomized multicentre trial of the Medoff sliding plate versus three other screw plate systems. *Acta Orthop Scand.* 2001;72(2):133-40.

Cite this article as: Singla G. A comparative study of 70 cases of inter-trochanteric fracture femur treated with dynamic hip screw and proximal femoral nailing. *Int J Res Orthop* 2017;3:293-7.